

## DONGDONG'S JOURNEY




July 10, 2009

You can't help but smile when SheDong flashes an adorable gap-filled grin, which he does almost all the time these days. But, "DongDong" as his caregivers affectionately call him, was not always this cheerful.

DongDong was abandoned when he was just days old and arrived at China Care with a cleft lip and palate and a double ear infection. Since his split lip and palate made it difficult to eat, he was also extremely weak, weighing barely 5 ½ pounds.

In his first few days with us, DongDong could not be consoled. He cried endlessly as his caregivers patiently attempted to comfort him and nourish him through a feeding tube. Finally, at the end of that week, DongDong was able to drink milk on his own. His cheeks filled out and as one caregiver gushed, "he started to look awfully cute!"



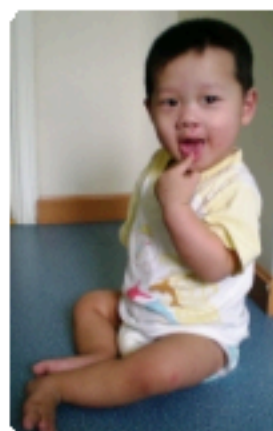Soon DongDong was able to crawl by himself and make hand signals when he wanted to say "thanks" or "welcome." Today, the boy who would not stop crying is rarely seen without an endearing smile on his face. In fact, he jumps into just about anyone's open arms with a boisterous giggle.



One morning DongDong's caregiver noticed he kept kissing her repeatedly on the cheek when she was holding him. She thought it was funny until she felt something hard rubbing her face and realized he was using her face as a teether!

In early May, DongDong moved with more than two dozen of his "brothers and sisters" into the new China Care Home in Beijing. One of his nannies said, "It's hard to believe after surgery this little boy will be even more handsome than he already is!"

DongDong had the surgery to repair his cleft lip and palate in July 2009 and is currently recovering at the China Care Home in Beijing.



*DongDong after surgery*